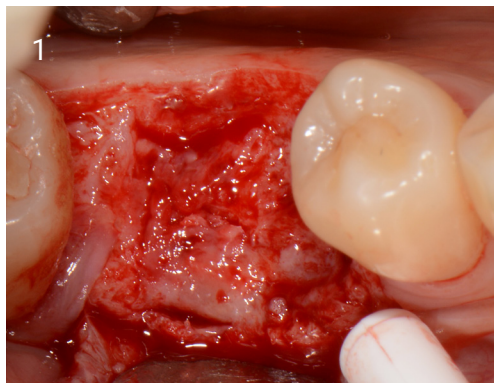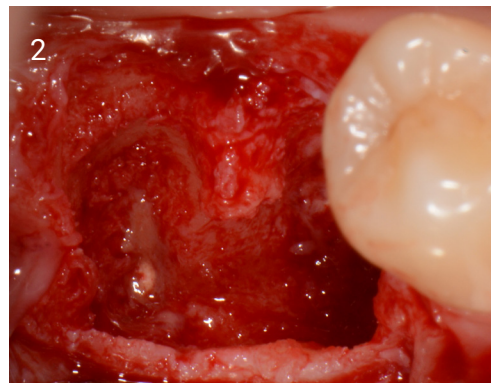
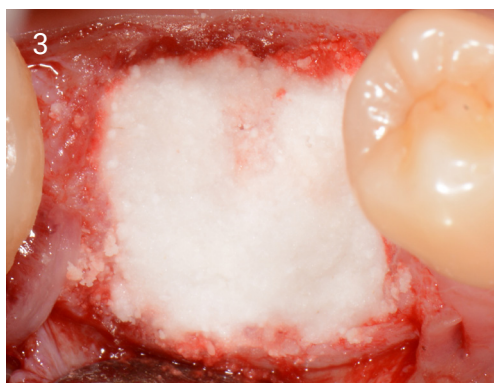


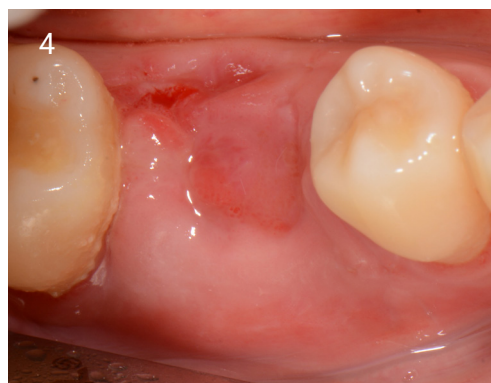1. 3 weeks post extraction flap raised to show granulation tissue.



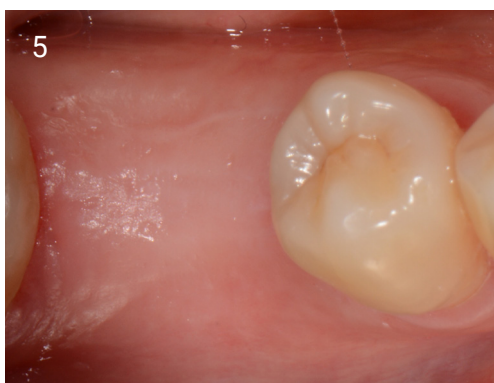2. Site cleaned with EthOss® Degranulation Bur.



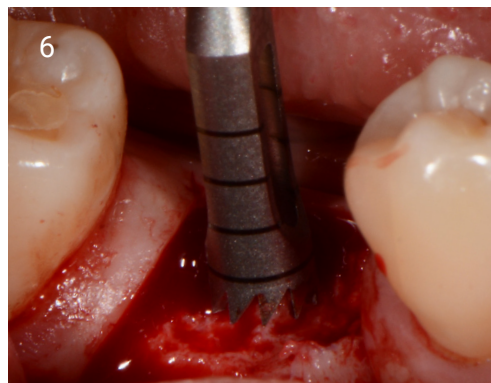
3. Grafted with EthOss® to ridge level.



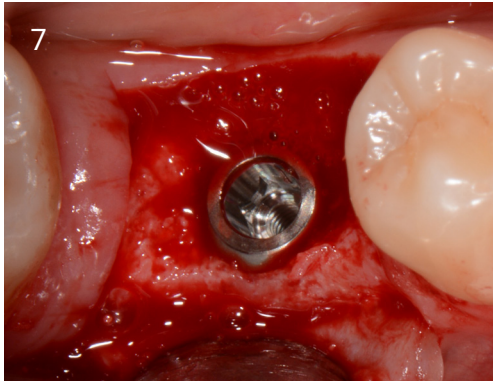
4. Healed site 5 days later - sutures removed.



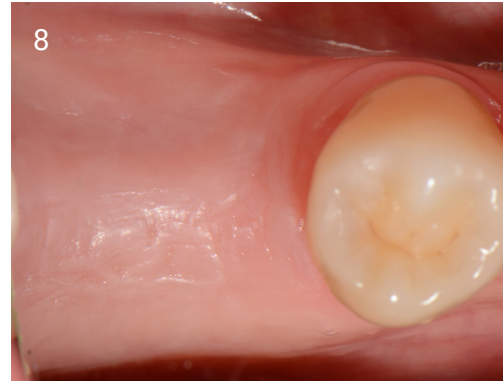5. 12 weeks later healed site.



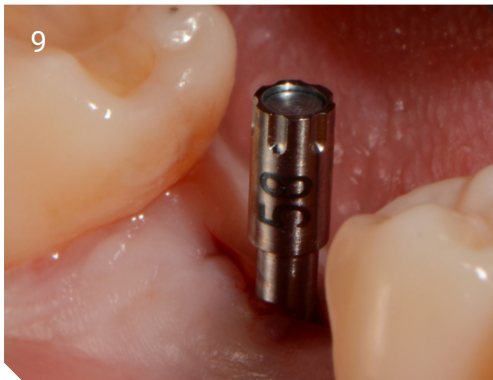6. Core Sample being taken and sent for histological analysis (see 18).



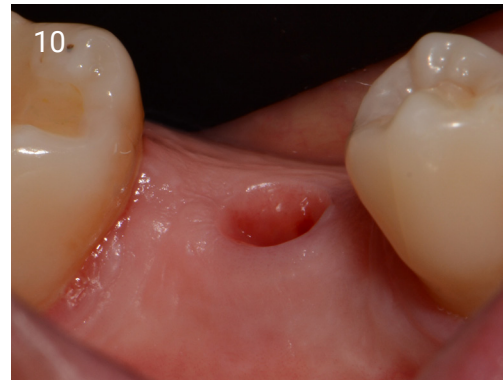7. Implant placed, Osstell meter used to measure stability, reading at 62 ISQ.



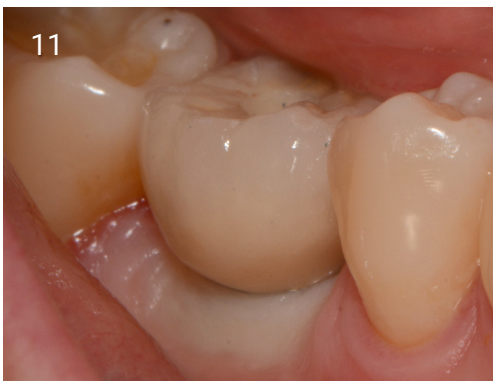8. Ready to load at 10 weeks , healthy attached gingiva.



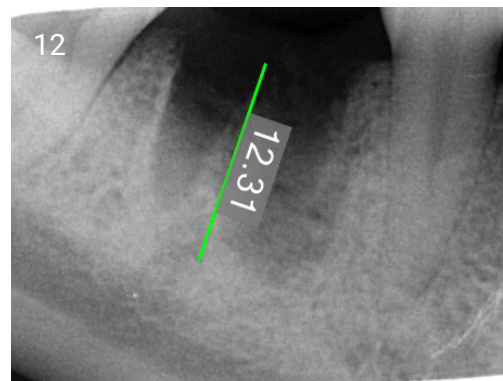
9. Osstell reading taken - now 75 ISQ.



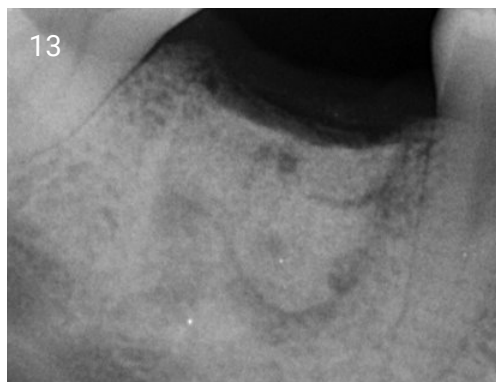
10. Healed peri-implant soft tissue.



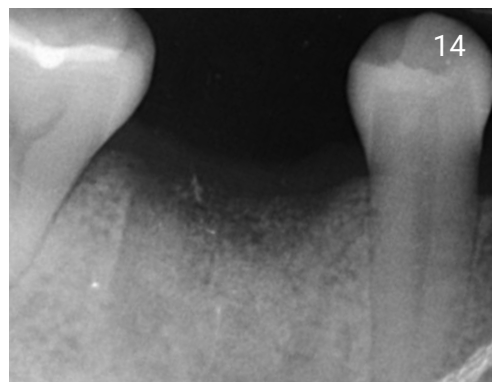
11. Loaded Case.



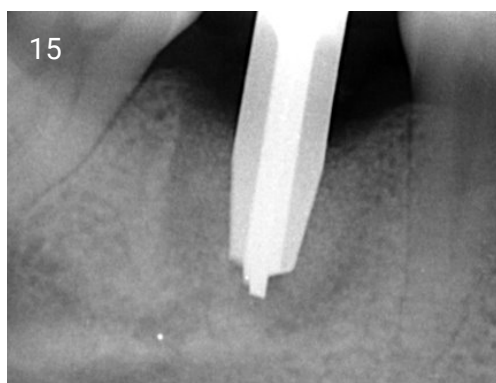
12. Radiograph of cleaned site, before grafting.



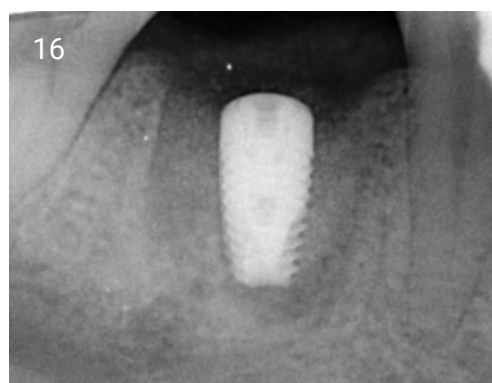
13. Radiograph of grafted site.



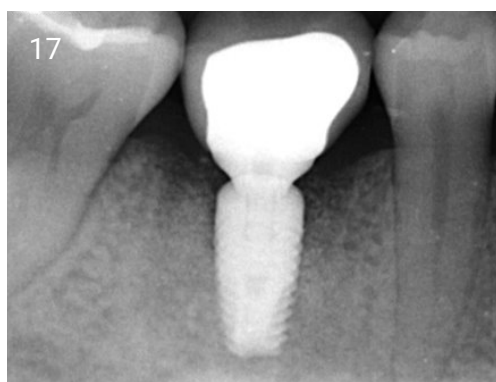
14. Radiograph at 12 weeks.



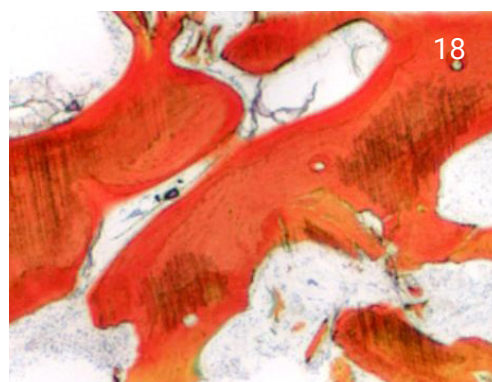
15. Osteotomy in core site.



16. Radiograph of placed Implant.



17. Radiograph of loaded case.



18. Histology of core from University of Minnesota, showing 50% new bone at 12 weeks.